

Syndesmosis Repair: 14 Patient Case Series

Sarang Desai, DO

Orthopedics Sports & Spine, McKinney, TX

Appropriate treatment for stabilization of the ankle syndesmosis has been controversial for many years. The author presents a case series in which the FIBULINK™ Syndesmosis Repair System was used to treat 14 patients, including an overview of the surgical technique. The mean average follow-up time was 9.5 months. No complications were reported.

Injury Classifications: Supination External Rotation (n=9), Pronation External Rotation (n=2), Maisonneuve (n=1), Isolated Syndesmotic (n=2)

1. INTRODUCTION

Injuries to the syndesmosis have been reported to occur in 1%-18% of ankle sprains, and 13%-50% of ankle fractures.¹ The prompt identification and accurate reduction of these injuries are of utmost importance. Unrecognized syndesmosis injuries and malreduction have been found to result in significant morbidity including persistent pain, instability, and post-traumatic arthritis.²⁻³

Historically, the gold standard for syndesmosis fixation has been screw fixation; however, multiple issues have been reported related to this type of fixation, and the general concept of fixing a mobile joint with a rigid device. Potential issues related to screw fixation include: screw breakage in up to 36% of cases, screw loosening, potential second operations for screw removal with subsequent increases in cost, and malreduction.³⁻⁸ As a result of these concerns and the growing understanding of the natural motion of the syndesmosis, flexible suture button suspensory constructs have gained traction. Potential advantages of these constructs include: promoting physiologic motion of the syndesmosis, accelerated rehabilitation,⁹ device aiding in

accurate reduction,⁶ helping prevent malreduction,⁷ maintaining reduction,⁹ and decreased cost as the implant does not theoretically require removal.⁴ Many drawbacks of these devices have also been reported including: soft tissue complications,¹⁰ osteomyelitis,¹¹ painful aseptic osteolysis,¹¹ tibialis anterior tendon entrapment,¹² difficulty in treating axially unstable injuries because of translation of the suture in the bone tunnel,^{13,14} failed stabilization of the syndesmosis,¹³ syndesmosis overcompression,¹⁵ damage to the superficial medial neurovascular bundle,¹⁶ and pull-through of the buttons.¹¹

The FIBULINK Syndesmosis Repair System is a unique¹ flexible fixation device that promotes physiologic motion of the syndesmosis, retains the tibial fixation of a screw, eliminates medial soft tissue disruption, while allowing fine adjustment by the surgeon to dial in their desired reduction. The system became clinically available in 2017. The purpose of this case series is to discuss 14 patients who received the FIBULINK Implant and assess their follow-up.

CASE SERIES

2. SURGICAL TECHNIQUE

2.1 Preoperative

The ankle is evaluated using the routine techniques per the surgeon's preference. These modalities may include radiographs, CT, or MRI. Intraoperative examination using direct inspection, along with fluoroscopy, are important tools to identify these injuries.

2.2 Intraoperative

If fractures are associated with the syndesmosis injury, they will first be fixed anatomically. Next, the syndesmosis is reduced under direct inspection, confirming the fibula is anatomically reduced in the incisura. The author prefers simple thumb pressure to maintain reduction of the syndesmosis. Alternatively, a clamp can be used to maintain reduction; however, caution should be used to confirm the clamp is not overcompressing the joint or leading to a malreduction (Figure 1).

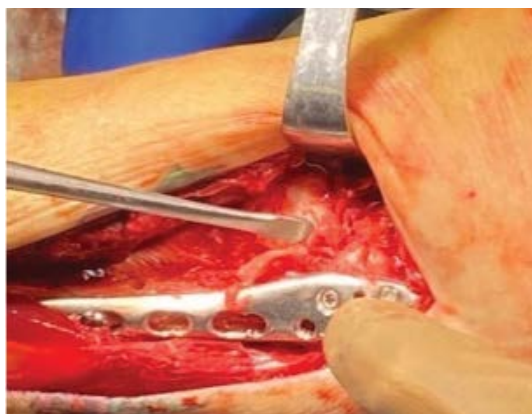


Figure 1. Thumb reduction technique

All instrumentation required to insert the FIBULINK Implant is provided in a single-use sterile kit (Figure 2).



Figure 2. FIBULINK Implant Kit

While maintaining reduction, and with the aid of fluoroscopy, the K-wire is then introduced through the fibula into the tibia 2-3 cm proximal and parallel to the joint line, with a 20-30 degree anterior trajectory. The K-wire should not penetrate the medial cortex of the tibia, so to not damage the saphenous neurovascular bundle (Figure 3).

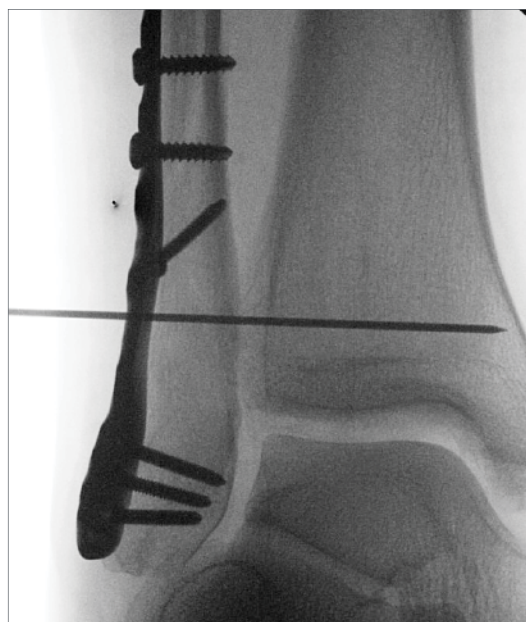

Figure 3. K-Wire Placement

CASE SERIES

Next, the cannulated step drill is used to carefully drill the fibula and tibia (Figure 4 A,B). It is very important to not penetrate the tibia with the larger portion of the drill. Fluoroscopy should be used throughout this portion of the procedure. The drill and wire are then removed.

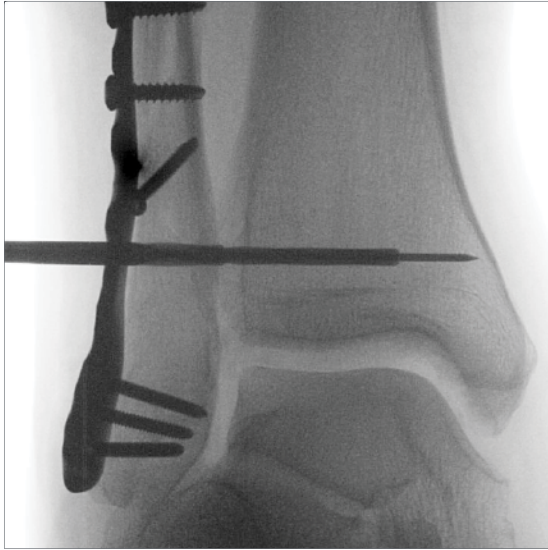

Figure 4. (A) Step Drill

The tibial screw, which comes pre-attached to the driver, is advanced into the tibia. The surgeon will typically feel an increase in torque as the shoulder of the driver abuts the lateral cortex of the tibia. A mortise view with fluoroscopy should be obtained to confirm the tibial screw is fully seated and flush with the lateral tibial cortex, referencing the line of the fibula incisura.

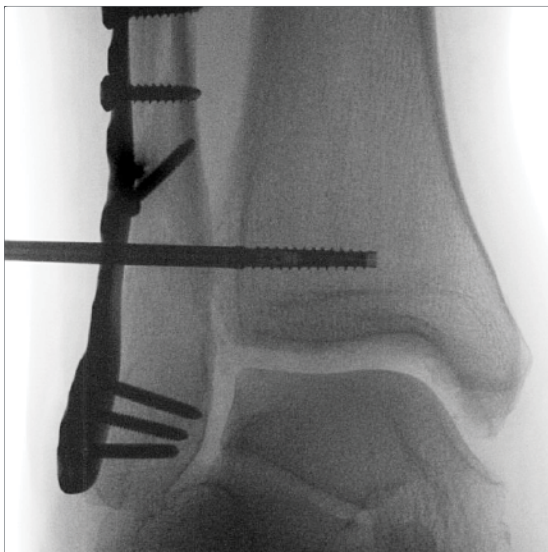

Figure 4. (B) Tibia screw placement

At this point the surgeon will visualize the laser line on the driver. If the laser line is clearly visualized above the level of the plate, the standard fibular tensioning cap, which comes pre-attached to the tensioning knob, is used. If the laser line is below the level of the plate, the shorter, pre-attached standard tensioning cap will be exchanged for the longer fibular tensioning cap.

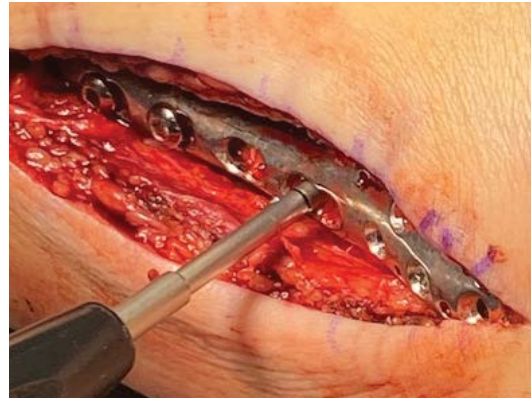


Figure 5. Indicator Groove

Next, the suture will be unwound from the driver handle and the driver is pulled laterally to remove it. The tensioning knob with the appropriate fibula tensioning cap is placed over the guide tubes and slid into the hole drilled in the fibula. A hemostat is then clamped to the silver guide tube, and the guide tubes are pulled laterally to engage the external threads of the link to the internal threads of the tensioning cap.

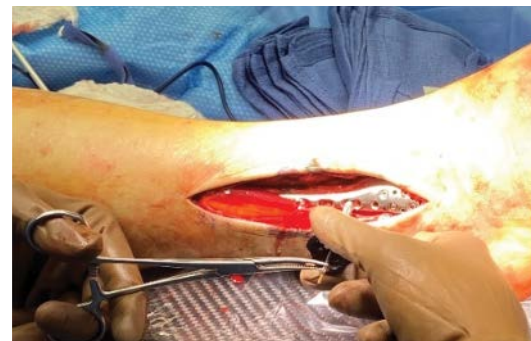

Figure 6. Link deployment and tensioning

The fibula tensioning cap is then advanced by clockwise rotation of the knob, which will increase tension, while counterclockwise rotation will reduce tension of the device. This allows the surgeon to perform fine adjustments of the FIBULINK System to ensure an anatomic reduction. Direct inspection of the fibula at the incisura, as well as fluoroscopy, is used to confirm. When the surgeon is content with the syndesmosis reduction, the silver tube, followed by the gold tube, then tensioning knob are each pulled laterally to remove.

CASE SERIES

2.3 Postoperatively

The postoperative course will vary depending on surgeon preference and the type of injury. The author's preference is to maintain a non-weight-bearing status for 6 weeks, followed by progressive weight-bearing in a walking boot for 3 weeks. Depending on radiographic and clinical progress, the patient is then allowed a lace-up ankle brace and tennis shoe between 2 to 3 months. Formal rehabilitation will be essential for an optimal outcome. Full recovery may take at least 12 months.

2.4 Clinical Data

The author published a case series of 14 patients treated with the FIBULINK System in *Techniques in Foot & Ankle Surgery*.¹ The series included 9 supination-external rotation (SER) injuries (Figure 7 A,B; 2 pronation external rotation (PER) injuries (Figure 8 A,B); 1 Maisonneuve injury (Figure 9 A,B); and 2 isolated syndesmosis injuries. The SER injuries underwent open reduction internal fixation (ORIF) of the lateral malleolus, and medial malleolus fracture when present, followed by one FIBULINK Implant. The PER injuries underwent ORIF of the fibula and repair of the deltoid, followed by one FIBULINK Implant to stabilize the syndesmosis. The Maisonneuve fracture and isolated syndesmosis injuries were stabilized by a 3-hole tubular plate with two FIBULINK Implants.

Average time of follow-up was 9.5 months. At the last follow-up, all patients had favorable results with American Orthopedic Foot and Ankle Society and Visual Analog Scale scoring systems (mean score of 94, varying slightly by type of injury, gender, and age, with a range of 97-100) along with radiographically healed fractures without rewidening of the syndesmosis. There were no complications in this series.

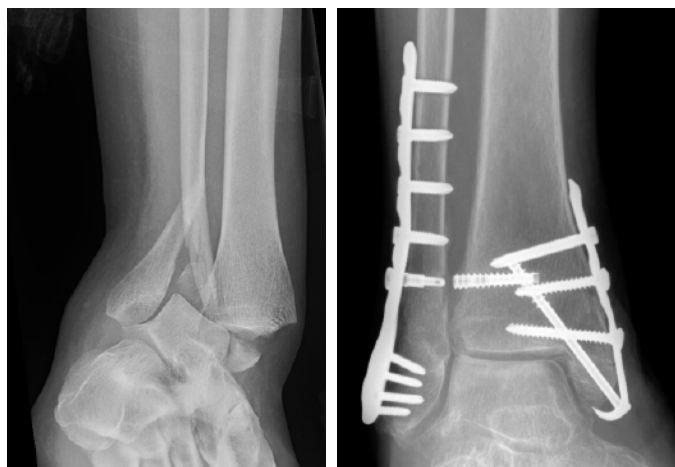

Figure 7. (A) SER Injury (B) 12-month follow-up

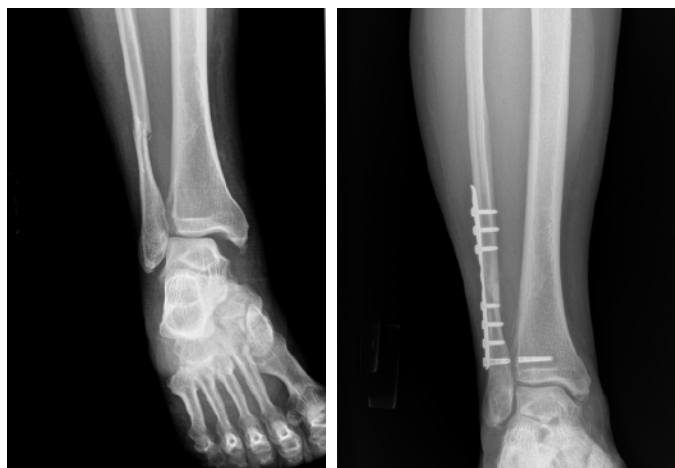

Figure 8. (A) PER Injury (B) 9-month follow-up

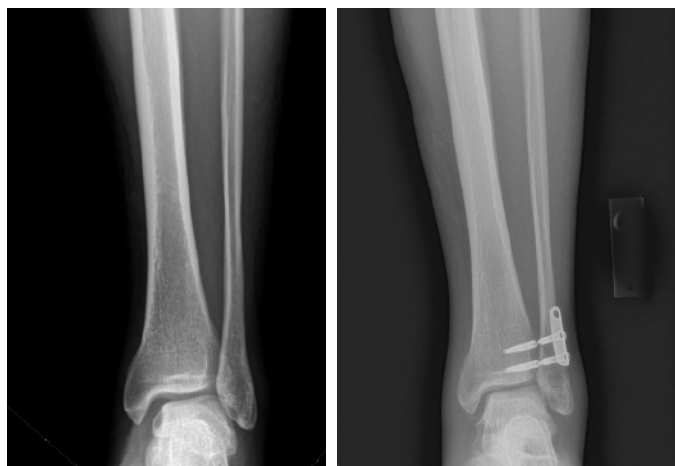

Figure 9. (A) Maisonneuve Injury (B) 10-month follow-up

CASE SERIES

3. DISCUSSION

Prior to availability of the FIBULINK System, the two main choices for syndesmotom fixation included syndesmotom screws and suture button devices. Syndesmotom screws provide limited ability to retain the joint mechanics of the syndesmosis and frequently result in implant failure. While suture button constructs achieve improved joint mechanics, several drawbacks still exist.^{1,10-16}

The DePuy Synthes FIBULINK Syndesmosis Repair System composing of a threaded tibia anchor, short fixed length suture bridge, and telescoping fibular anchor is described. The device retains the potential advantages of other suspensory fixation devices. These include maintaining physiologic syndesmosis motion, toggling the fibula into the incisura to promote an anatomic reduction, helping prevent malreduction, accelerated rehabilitation,⁹ retaining reduction, and potential cost savings, as the device has no theoretical need for removal.

The novel technique presented here offers several advantages over traditional syndesmosis fixation devices. Damage to the saphenous neurovascular bundle, a second incision, and medial soft tissue complications are eliminated as the device does not include a medial button. A key benefit of the FIBULINK Implant is the ability of the surgeon to “dial in” the reduction by easily increasing or decreasing tension of the construct. Biomechanically, the device offers “aperture fixation” (fixation at the level of the joint) through a lateral tibia screw and short suture bridge spanning the joint, stabilizing the disrupted ligaments in the region of their origin and insertion. This provides more strength and stiffness and less stretch and creep compared to suspensory suture button devices with long suture bridges.¹ This promotes a long-term syndesmosis reduction without rewidening.

4. CONCLUSION

A case series of 14 patients was presented with no complications at a mean follow-up of 9.5 months. Although the short-term data are promising, long-term data are needed. A prospective randomized trial comparing the FIBULINK System to suture button constructs would be beneficial.

5. SURGEON PROFILE

Sarang Desai, DO

Orthopedics Sports & Spine
McKinney, TX



Dr. Desai contributed to the development and was an early adopter of the FIBULINK System when it was previously distributed through AKROS Medical.

6. REFERENCES

1. Desai S. Syndesmotic injuries treated with an aperture fixation device. *Techniques in Foot & Ankle Surg.* 2020;19(2):96-103
2. Sagi HC, Shah AR, Sanders RW. The functional consequence of syndesmotic joint malreduction at a minimum 2-year follow-up. *Journal of orthopaedic trauma.* 2012;26(7):439-443.
3. van Vlijmen N, Denk K, van Kampen A, et al. Long-term results after ankle syndesmosis injuries. *Orthopedics.* 2015;38:e1001-e1006.
4. Neary KC, Mormino MA, Wang H. Suture button fixation versus syndesmotic screw in supination-external rotation type 4 injuries: a costeffectiveness analysis. *Am J Sports Med.* 2017;45:210-217.
5. Laflamme M, Belzile EL, Bédard L, et al. A prospective randomized multicenter trial comparing clinical outcomes of patients treated surgically with a static or dynamic implant for acute ankle syndesmosis rupture. *J Orthop Trauma.* 2015;29:216-223.
6. Westermann RW, Rungprai C, Goetz JE, Femino J, Amendola A, Phisitkul P. The effect of suture-button fixation on simulated syndesmotic malreduction: a cadaveric study. *The Journal of bone and joint surgery American volume.* 2014;96(20):1732-1738.
7. Naqvi GA, Cunningham P, Lynch B, et al. Fixation of ankle syndesmotic injuries: comparison of tightrope fixation and syndesmotic screw fixation for accuracy of syndesmotic reduction. *J Foot Ankle Surg.* 2013;52:563-567.
8. Rigby RB, Cottom JM. Does the Arthrex TightRope® provide maintenance of the distal tibiofibular syndesmosis? A 2-year follow-up of 64 TightRopes® in 37 patients. *The Journal of foot and ankle surgery: official publication of the American College of Foot and Ankle Surgeons.* 2013;52(5):563-567.
9. Qamar F, Kadakia A, Venkateswaran B. An anatomical way of treating ankle syndesmotic injuries. *J Foot Ankle Surg.* 2011;50(6):762-765.
10. Naqvi GA, Shafqat A, Awan N. Tightrope fixation of ankle syndesmosis injuries: Clinical outcome, complications and technique modification. *Injury.* 2012;43(6):838-842.
11. Storey P, Gadd RJ, Blundell C, et al. Complications of suture button ankle syndesmosis stabilization with modifications of surgical technique. *Foot Ankle Int.* 2012;33:717-721.
12. Welck MJ, Ray P. Tibialis anterior tendon entrapment after ankle tightrope insertion for acute syndesmosis injury. *Foot Ankle Spec.* 2013;6:242-246.
13. Ibnu Samsudin M, Yap MQW, Wei Luong A, et al. Slippage of tightrope button in syndesmotic fixation of Weber C malleolar fractures: a case series. *Foot Ankle Int.* 2018;39:613-617.
14. Riedel MD, Miller CP, Kwon JY. Augmenting suture-button fixation for Maisonneuve injuries with fibular shortening: technique tip. *Foot Ankle Int.* 2017;38:1146-1151.
15. Schon JM, Mikula JD, Backus JD, et al. 3D model analysis of ankle flexion on anatomic reduction of a syndesmotic injury. *Foot Ankle Int.* 2017;38:364-442.
16. Pirozzi KM, Creech CL, Meyr AJ. Assessment of anatomic risk during syndesmotic stabilization with the suture button technique. *J Foot Ankle Surg.* 2015;54:917-919.

Results from case studies are not predictive of results in other cases. Results in other cases may vary.

Please refer to the instructions for use for a complete list of indications, contraindications, warnings and precautions.



© DePuy Synthes 2021. All rights reserved.
156741-210813 DSUS/EMEA

Manufactured by:
Synthes GmbH
Luzernstrasse 21
4528 Zuchwil
Switzerland

www.depuyssynthes.com

Synthes GmbH
Eimattstrasse 3
4436 Oberdorf
Switzerland
Tel: +41 61 965 61 11